



PATIENT PRESENTING CLINICAL SIGNS

Axel Infanti Running in woods on big hike - lept 10 feet came up lame after. Non weight bearing since Very sore.
Abnormal PE/Chem/CBC/UA Results: Full CCL tear, Marked Cranial drawer, CTT

SPECIES

The patient name attached to the image files is Michael Sperney. Patient history says Axel Infanti.
Canine

ULTRASONOGRAPHIC STUDY OF THE RIGHT STIFLE JOINT

BREED

ULTRASONOGRAPHIC FINDINGS

Dachshund Mix Moderate anechoic effusion is distending the supra and infrapatellar recesses with associated synovial thickening. Detached hypoechoic fibers of the cranial cruciate ligament are seen within the infrapatellar recess surrounded by an anechoic halo. Heterogeneity of the infrapatellar fat pad is noted.

SEX

MN The medial meniscus is in situ and presents mild internal heterogeneity. The lateral meniscus is in situ and uniformly hypoechoic. Thickening of the medial collateral ligament is seen.

AGE

4yr

ULTRASONOGRAPHIC DIAGNOSIS

- Complete rupture of the right cranial cruciate ligament
- Severe synovitis and joint effusion
- Severe osteoarthritic changes of the right stifle
- Desmitis of the medial collateral ligament: secondary to osteoarthritis
- Mild degenerative changes of the medial meniscus without displacement or structural tearing

INTERPRETED BY

Nele Eley (Ondreka),
DVM Dr. med. vet.,
DipECVDI

INTERPRETATION OF FINDINGS & FURTHER RECOMMENDATIONS

The ultrasonographic findings are consistent with fully ruptured cranial cruciate ligament with concomitant synovitis and advanced osteoarthritis. The medial meniscal integrity appears largely preserved ultrasonographically though degenerative changes of the medial meniscus are suspected.

HOSPITAL NAME

Westview Veterinary
Hospital

Surgical stabilization is indicated and has been performed already in order to prevent further damage to the joint.

REFERRING VET

Dr Brian Barnes

INVOICE

23267

DATE

12/17/2025



PATIENT

Axel Infanti

SPECIES

Canine

BREED

Dachshund Mix

SEX

MN

AGE

4yr

INTERPRETED BY

Nele Eley (Ondreka),
DVM Dr. med. vet.,
DipECVDI

HOSPITAL NAME

Westview Veterinary
Hospital

REFERRING VET

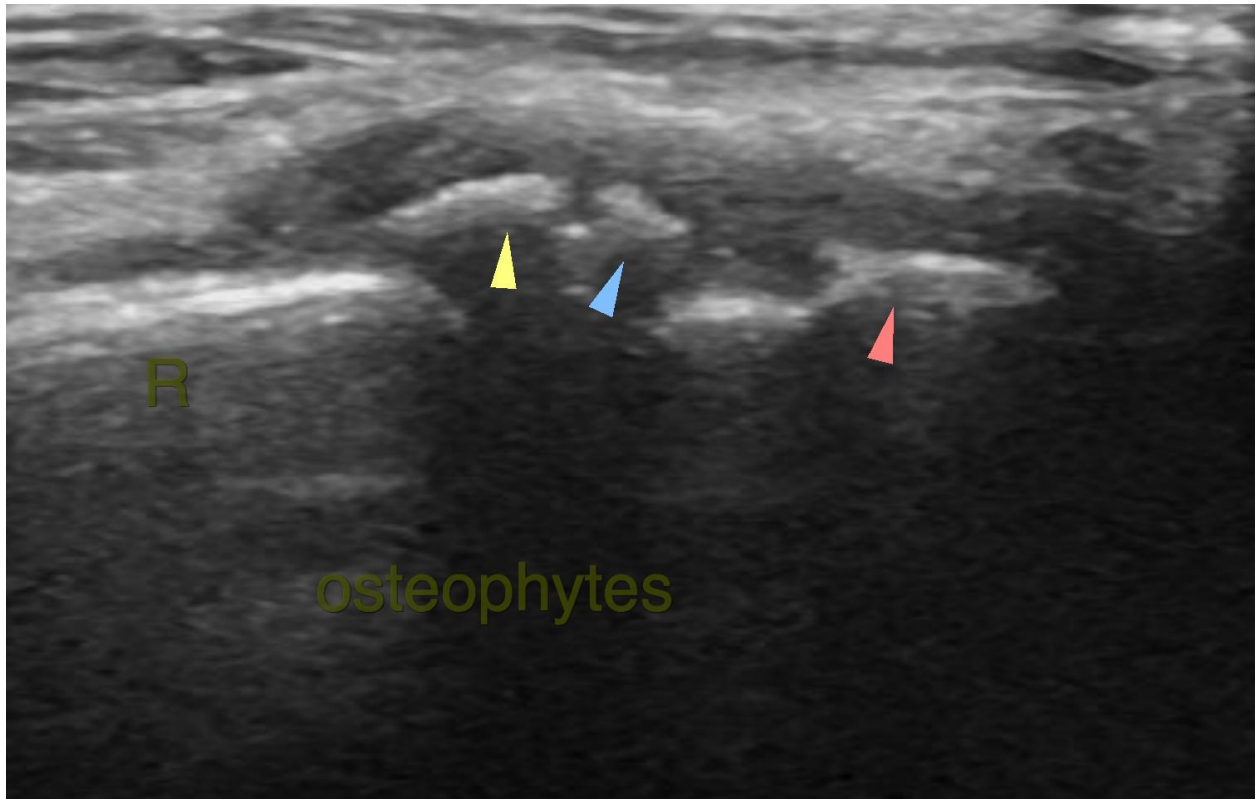
Dr Brian Barnes

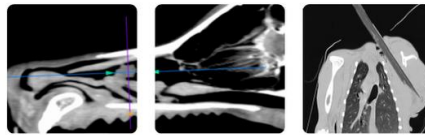
INVOICE

23267

DATE

12/17/2025





PATIENT

Axel Infanti

SPECIES

Canine

BREED

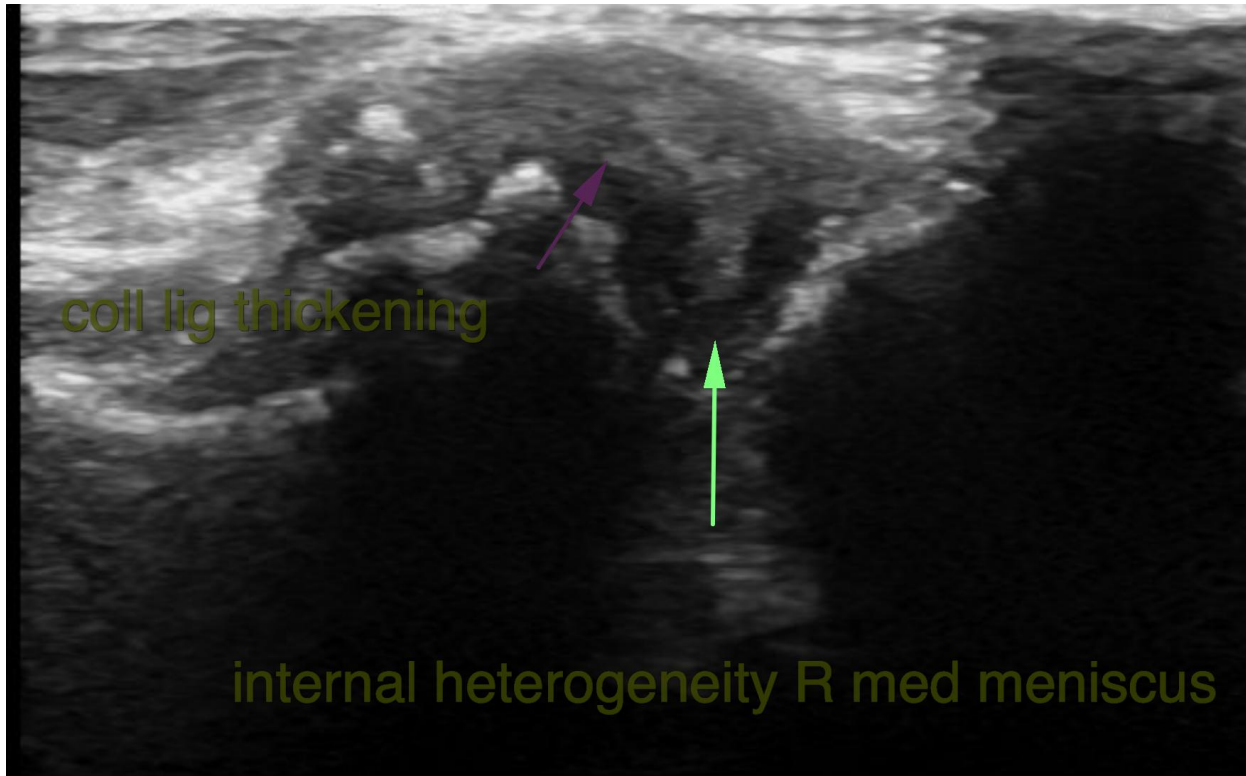
Dachshund Mix

SEX

MN

AGE

4yr



INTERPRETED BY

Nele Eley (Ondreka),
DVM Dr. med. vet.,
DipECVDI

HOSPITAL NAME

Westview Veterinary
Hospital

REFERRING VET

Dr Brian Barnes

INVOICE

23267

DATE

12/17/2025



PATIENT

Axel Infanti

SPECIES

Canine

BREED

Dachshund Mix

SEX

MN

AGE

4yr

INTERPRETED BY

Nele Eley (Ondreka),
DVM Dr. med. vet.,
DipECVDI

HOSPITAL NAME

Westview Veterinary
Hospital

REFERRING VET

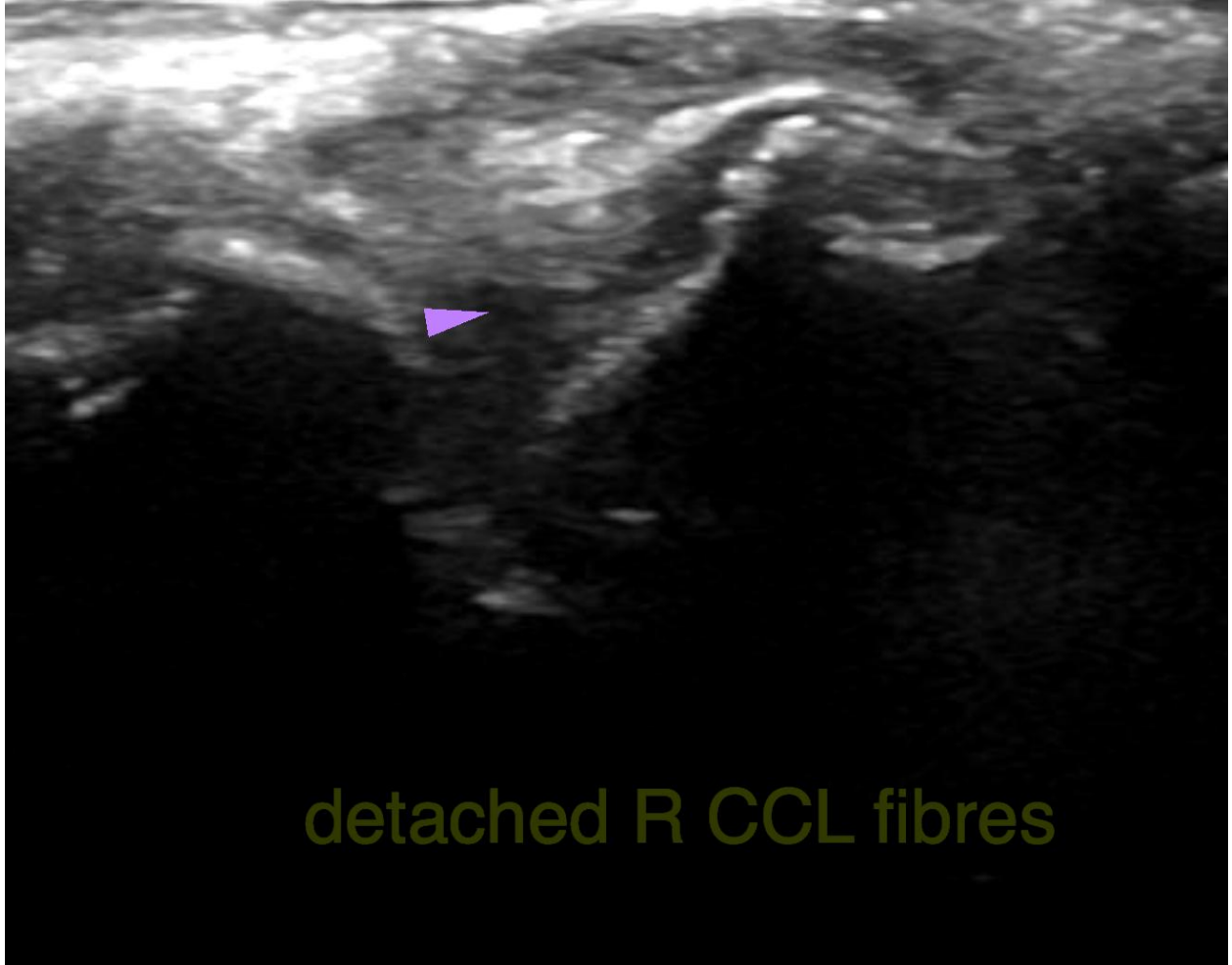
Dr Brian Barnes

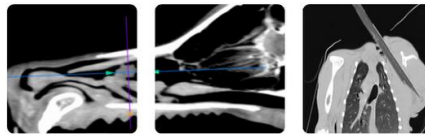
INVOICE

23267

DATE

12/17/2025





Teleradiology

Educational Teleconsultation Services™

PATIENT

Axel Infanti

The information and recommendations provided are based on the images presented by the referring veterinarian. No evaluation can be communicated regarding pathology that was not visible in the image/video clips provided.

SPECIES

Canine

Thank you for this referral. If the clinical or image interpretation does not parallel your findings or if I can be of any further assistance please contact me.

BREED

Dachshund Mix

Nele Eley (Ondreka), DVM, Dr. med. vet., DipECVDI
European Specialist in Veterinary Diagnostic Imaging, Cert. Radiology,
Senior lecturer University of Giessen/Germany, Veterinary Faculty, Department of Radiology.
info@sonopath.com

SEX

MN

AGE

4yr

INTERPRETED BY

Nele Eley (Ondreka),
DVM Dr. med. vet.,
DipECVDI

HOSPITAL NAME

Westview Veterinary
Hospital

REFERRING VET

Dr Brian Barnes

INVOICE

23267

DATE

12/17/2025